



PRESENTING CLINICAL SIGNS

History: Recheck degenerative valve disease. Receiving pimobendan 2.5 mg BID.

DATE

8/18/23

ECHOCARDIOGRAPHIC FINDINGS

2D, M-mode, and Doppler study. This exam is compared to the one performed 12/23/22.

PERFORMED BY:

Shari Reffi, CVT

INTERPRETED BY

Keith Blass, DVM,
MS, DACVIM
(Cardiology)

There is mild left atrial dilation. The mitral valve leaflets are mildly thickened and exhibit mild systolic prolapse. A mild to moderate jet of eccentric mitral regurgitation is present. There is mild left ventricular dilation. Left ventricular systolic function is normal. The aorta and aortic valve appear normal, though there is mildly increased flow velocity in the ascending aorta. Right atrial and right ventricular dimensions are normal. The tricuspid valve appears normal, though trace tricuspid regurgitation is present. The pulmonary artery and pulmonic valve are normal. No shunting lesions are visualized. No heartworms are visualized. No pericardial effusion or cardiac masses are seen.

PATIENT

Josie Godoy

LA - 31.5 mm (prev. 32.0 mm)
LVIDd - 30.3 mm (prev. 30.8 mm)
LVIDs - 17.4 mm (prev. 18.0 mm)
FS - 42.6% (prev. 41.6%)
RA - 18.1 mm (prev. 15.7 mm)
LVOT - 2.75 m/s (prev. 1.37 m/s)
RVOT - 1.17 m/s (prev. 0.96 m/s)

SPECIES

Canine

ASSESSMENT/RECOMMENDATIONS

Degenerative mitral valve disease

BREED

Min. Schnauzer

This examination demonstrates no progression of Josie's mitral valve disease over the past 8 months. As such, Josie's current risk for the development of clinical signs secondary to his disease, such as coughing, exercise intolerance, syncope, and labored breathing, still appears to be relatively low, though careful monitoring for these signs is still recommended.

No change in therapy is recommended at this time.

SEX

A recheck echocardiogram is recommended in 9 months. Thoracic radiographs are recommended if Josie experiences respiratory clinical signs.

MN

AGE

10 y

WEIGHT

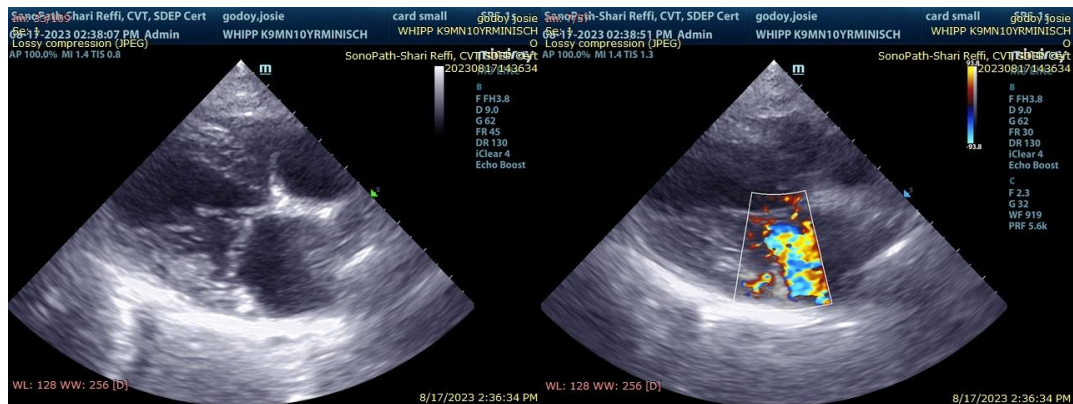
19.5 lb

HOSPITAL NAME

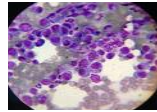
Whippany VH

REFERRING VET

Dr. Cordero



The information and recommendations provided are based on the images presented by the referring veterinarian. No evaluation can be communicated regarding pathology that was not visible in the image/video clips provided.



Thank you for this referral. If the clinical or image interpretation does not parallel your findings or if I can be of any further assistance please contact me.

DATE

8/18/23

Keith Blass, DVM, MS, DACVIM (Cardiology)
KeithBlass@gmail.com
631-804-5754

PERFORMED BY:

Shari Reffi, CVT

INTERPRETED BY

Keith Blass, DVM,
MS, DACVIM
(Cardiology)

PATIENT

Josie Godoy

SPECIES

Canine

BREED

Min. Schnauzer

SEX

MN

AGE

10 y

WEIGHT

19.5 lb

HOSPITAL NAME

Whippany VH

REFERRING VET

Dr. Cordero